

Frequency Rhythmic Electrical Modulation System in the treatment of diabetic ulcers

Preliminary encouraging report

A. MARGARA, F. BORIANI, F. D. OBBIALERO, M. A. BOCCHIOTTI

Estratto da CHIRURGIA

Vol. 21 - N. 6 - Pag. 311-314 (Dicembre 2008)

EDIZIONI MINERVA MEDICA - TORINO

Frequency Rhythmic Electrical Modulation System in the treatment of diabetic ulcers

Preliminary encouraging report

A. MARGARA, F. BORIANI, F. D. OBBIALERO, M. A. BOCCHIOTTI

*Department of Plastic Surgery
University of Turin, Turin, Italy*

Aim. Skin ulcers often accompany neuropathy and vascular compromise in what is known as diabetic foot. In the literature no mention of electric stimulation is given in the guidelines for diabetic foot management, usually consisting of wound dressing and, if necessary, reconstructive surgery. The aim of this study was to assess the effectiveness of Frequency Rhythmic Electrical Modulation System (FREMS) in association with the traditional treatment of diabetic foot.

Methods. Thirty patients suffering from diabetic foot were divided into 2 groups. Group A (16 patients) was treated with FREMS in association with classical therapy, whereas group B (14 patients) underwent only the traditional treatment, consisting of wound dressing. Ulcer size was measured three times during a two-month observation period.

Results. The wound shrinking rate was significantly higher in group A, at least at first and second measurement ($P < 0.05$).

Conclusion. Even though the number of patients studied is limited, FREMS has shown to be of some benefit in the treatment of diabetic foot. This therapy accelerates wound healing and reduces pain associated both to ulcers and to diabetic neuropathy. If the clinical findings reported by the authors are confirmed by studies on larger series of patients, FREMS can be proposed as a useful device to combine with classical treatment of diabetic foot.

KEY WORDS: Skin ulcer - Diabetic foot - Electric stimulation - Diabetes.

Skin ulcers are a very common diabetes-related complication that mostly involves the foot. Aetiologic factors are the local neuropathy that interferes with pain sensation, the peripheral vascular disease and the immunocompromise which both contribute to a less efficient wound healing.

A recent study¹ has created a multidisciplinary, evidence-based, clinical guideline for the assessment, investigation and management of acute diabetes related foot complications. It distinguishes the four principal causative factors (neuropathy, vascular compromise, ulceration and infection) in the development of acute diabetes foot-complications and suggests, within the clinical guideline, a specific classification system, which codes for the severity of the four pathophysiologic factors.

Received on March 16, 2007.

Accepted for publication on December 9, 2008.

Corresponding author: F. Boriani, Department of Plastic Surgery, University of Turin, San Lazzaro Hospital, via Cherasco 23, 10100 Turin, Italy. E-mail: filippo.boriani@fastwebnet.it

Electric stimulation was proposed 30 years ago as a valid solution for ulcer treatment especially for some pathologies caused by microvascular dysfunction or in case of resistance to the traditional therapy.²⁻⁸

Relevant results were obtained in diabetic patients in whom perfusion of ischemic areas and ulcer healing were achieved.^{9,10}

A recently described technique of treatment for diabetic foot is Frequency Rhythmic Electrical Modulation System (FREMS) whose effectiveness has been proven for the diabetic neuropathy.¹¹ Its action is based on angiogenesis and vasomotion as well as anti-inflammatory effect. Hence we hypothesized that FREMS could be of benefit also for diabetic ulcers and therefore assessed this therapy in a cohort of patients treated by us. Traditional treatment of diabetic ulcers of foot consists of medical management by means of dressings, antibiotic and vacuum-assisted closure or surgical approach, including debridement and reconstruction through skin grafts or flaps.¹²⁻¹⁷ By combining FREMS to traditional medical therapy we sought whether this association could improve wound healing, compared to the only traditional therapy.

Materials and methods

We gathered 30 patients suffering from diabetic ulcers to the feet and divided them into two groups; group A consisted of 16 patients (9 males and 7 women) treated with FREMS in association with traditional therapy for ulcers. Group B instead counted 14 patients (8 men and 6 women) treated with traditional therapy only. We excluded from the study all the patients presenting infection of the ulcer. Table I presents the characteristics of patients in group A and B.

Classical treatment consisted of wound dressings once a week or more frequently, based on single patient's need. Type of dressing and frequency of changes were chosen in accordance with the guidelines for ulcer treatment utilized in our hospital, following National Pressure Ulcer Advisory Panel advice.¹⁸⁻²⁰

TABLE I.—Characteristic of patients at baseline.

	Group A	Group B
Number of patients	16	14
Sex		
Males	9	8
Females	7	6
Age (years)	67.3±4.3	64.65±3.6
Duration of diabetes (years)	16.4±2.8	15.9±3.2
Type of diabetes (type 1/type 2)	5/11	6/8
Diabetes therapy (insulin, oral agents)	7/9	9/5
Ulcer initial surface (cm ²)	8.075±2.36	8.012±2.23
Ulcer stadium III*	11	10
Ulcer stadium IV*	5	4

*National Pressure Ulcer Advisory Panel classification.

FREMS is based on a series of biphasic, asymmetric, electrically balanced pulses that are studied and combined for a specific biophysical treatment through a multiparametric modulation (frequency, pulse duration, amplitude) of the provided electrical signal.

The range of amplitude set-up utilized is between 0 and -300V with high negative potential, amplitude variable between 10 and 40 microS and frequency ranging from 1 Hz and 1KHz.

Different frequencies produce different effects on the cell (proliferation, growth factors stimulation, antimicrobial effect).^{2, 3, 21-25}

FREMS applications is made by specific and dedicated superficial single use electrode with high conductivity.

FREMS was administered through 30 minute-sessions every other day, for one month, *i.e* each patients from group A underwent a total amount of 15 sessions. Electrodes were applied at the perimeter of ulcer (Figure 1), according to several schemes of electrode positioning, to be alternated at each session. Further electrodes were placed at determined sites of both leg for prevention of further ulcer developing.

Ulcers from either group were measured with regard to size of wound at determined times. Pain and local redness were also regularly assessed but as they are parameters not easily measurable in objective way, no statistics were performed on those values.

Data were collected at the beginning, after 30 days (T30), corresponding to 15 sessions of FREMS, 45 days (T45) and 60 days (T60) after the beginning of therapy. We assessed the obtained results by measuring the ulcer surface and calculating the healed portions. We evaluated the differences in wound shrinking between the two treatments using the Student's t test.

Results

After only a cycle of FREMS therapy on the experimental group, we found that ulcer improvement was significantly higher, compared to that of patients from the control group, treated in the meantime with only wound dressings.

We compared the degree of wound shrinking between the two groups at T30, T45 and T60. At T30 and T45 we found out that the wound shrank significantly more in group A than in group B.

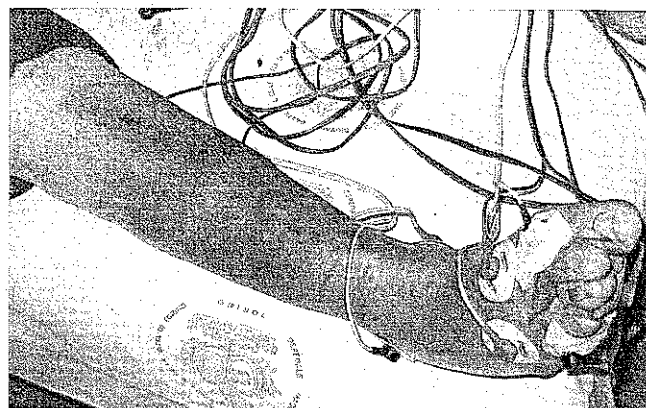


Figure 1.—Example of electrode positioning on the dorsum of a diabetic foot.

In group A at T30 the wound shrinking mean ratio towards initial size was 0.33 ± 0.22 , at T45 0.65 ± 0.14 and at T60 0.93 ± 0.11 . In group B the same values were respectively 0.14 ± 0.10 , 0.51 ± 0.14 and 0.83 ± 0.15 .

At T30 and T45 the degree of wound healing obtained in patients treated with FREMS was significantly higher than that achieved by simple dressings ($P<0.05$). On the other hand at T60 this significant difference was not obtained ($P>0.05$) (Figures 2-4).

Discussion

Although our study is based on a restricted number of cases, FREMS therapy has been proven to be efficient and safe for treatment of diabetic ulcers of the foot.

With regard to the mechanism of action producing the described benefits, it was not in the aim of our study and consequently it was not investigated. Some previous studies showed how this therapy yields some effects on local circulation and directly on cells. The application of electric currents below the muscular contraction threshold improves perfusion of ischemic tissues,²⁶ by promoting angiogenesis²⁷ and increasing capillary density. Electric stimulation contributes to the mechanism of tissue repair by acting on endothelial dysfunction and stimulating the production of growth factors,^{28, 29} endothelin-1 (ET-1) and nitric oxide (NO).^{30, 31} Electric stimulation intervenes on the unbalance between vasoconstrictor and vasodilator substances.

With regard to the action on cells, electric fields can move electric charges, present in human tissues as ions and through these can act on the cell membrane potential, thereby altering the physiologic, metabolic and immunologic functions of several types of cells.³² The cellular activity, in fact, is strictly related to the variation of membrane potential and consequently to the stimuli that can induce depolarization or repolarization.²¹ The biologic effect induced by electric fields on cells is strictly dependent on the technical parameters of the signal utilized, such as intensity, potential and frequency. The application of negative currents appeared particularly relevant for wound healing, as they induce important biologic effects, such as an antimicrobial action,^{2, 22} a reduction of the inflammatory phase with local decrease of neutrophils^{22, 23} and

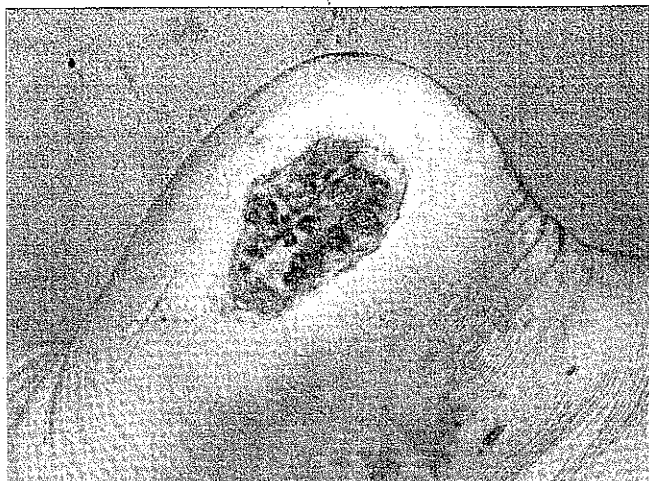


Figure 2.—Diabetic ulcer in calcaneal region at time T0 (patient from Group A).

macrophages,²² a stimulating effect on the cells involved in the reparative phenomena (epithelial cells, fibroblasts and myofibroblasts),^{21, 24, 25} and an increase of the proliferative phase on such cells.²²

Some preliminary studies proved that FREMS is capable of intervening on pathology of peripheral vessels¹¹ through amplification of vasomotion on microcirculation, followed by an improvement of respiratory gas exchanges. In fact the electric signals transmitted by this device produce an important biochemical interaction with peripheral deep tissues, thereby determining synthesis and release of growth factors, such as vascular endothelial growth factor (VEGF),³³ basic fibroblastic growth factor (b-FGF), platelet derived growth factor (PDGF) and epithelial growth factor (EGF), well known as regulators of tissue regeneration and angiogenesis. FREMS plays an anti-inflammatory role on tissues, with reduction of oedema, either for direct action on the immunitary system (long term effect), or by a modulation of specific cytokines, such as $\text{INF-}\alpha$ and $\text{TNF-}\alpha$ and by lymphatic drainage (immediate effect). Such actions allow a remarkable reduction of pain.^{11, 33} It is likely that FREMS, by improving the local trophism of tissues can provide a valid support to the treatment of ulcers and reduce the healing times for diabetic foot.³⁴ In patients suffering from diabetic foot it has been observed that FREMS eases production of granulation tissue and healing, or at least shrinking of plantar ulcers.^{35, 36}

Chronic wounds, such as diabetic ulcers of the foot, are susceptible of being treated with many therapies, including dressings, debridement/irrigation, pressure-relieving devices, hyperbaric or topically applied oxygen, whirlpool/pulsed lavage, ultrasound, topical antibiotics, and cytokines or growth factors. All said therapies except antibiotics and cytokines are physical interventions capable of improving the wound environment and thereby easing ulcer healing. Nevertheless in many cases tissue repair is very slow or absolutely absent, despite operators' efforts. The rationale for use of Electric Stimulation is based on the human endogenous bio-electric system that promotes wound healing^{37, 38, 39}. When this endogenous system is unable to promote tissue repair phenomena, an

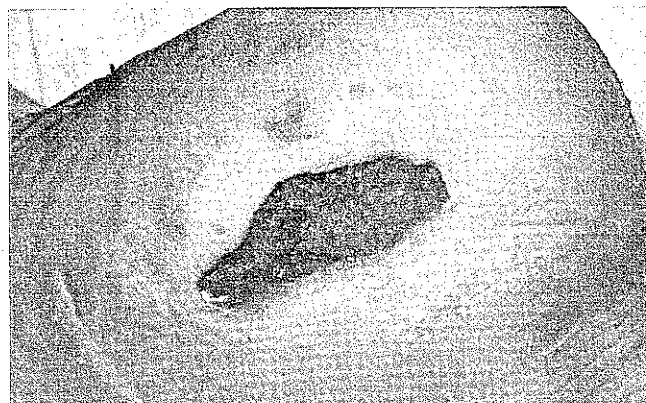

Figure 3.—Diabetic ulcer in calcaneal region at time T30 (patient from Group A).




Figure 4.—Diabetic ulcer in calcaneal region at time T60 (patient from Group A).

external source of electric currents can replace it, so that wound healing processes are still stimulated. FREMS, by simulating the failed natural bioelectric fields, induces a galvanotaxic attraction into the wound of several cells, such as neutrophils, macrophages, fibroblasts and epidermal cells. This facilitates granulation tissue formation and accelerates wound repair.

Conclusions

We therefore conclude that FREMS therapy appears as a useful device to combine with the other treatments utilized for diabetic foot. If the clinical findings found by authors are confirmed by larger series of cases, FREMS will be a new effective actor in the treatment of diabetic foot.

Riassunto

Sistema di neurostimolazione elettrica multiparametrica, modulata in frequenza, durata dell'impulso e nel tempo per il trattamento delle ulcere diabetiche. Dati preliminari incoraggianti

Obiettivo. Le ulcere cutanee accompagnano spesso la compromissione vascolare e la neuropatia che caratterizzano il piede diabetico.

Nella letteratura scientifica non vi sono dati sulla stimolazione elettrica nelle linee guida per la gestione del piede diabetico, che generalmente prevedono la toeletta chirurgica e, se necessario l'intervento chirurgico ricostruttivo. L'obiettivo di questo studio è stato quello di valutare l'efficacia della stimolazione elettromagnetica a modulazione di frequenza (Frequency Rhythmic Electrical Modulation System: FREMS) in associazione al trattamento tradizionale del piede diabetico.

Metodi. Un gruppo di pazienti con piede diabetico è stato suddiviso in 2 sottogruppi. Il Gruppo A (16 pazienti) è stato trattato con FREMS in associazione con la terapia classica, mentre il Gruppo B (14 pazienti) è stato sottoposto solo al trattamento tradizionale, consistente nella toeletta chirurgica. Le dimensioni dell'ulcera sono state misurate per tre volte durante un periodo di osservazione di due mesi.

Risultati. La riduzione percentuale delle dimensioni della ferita è stata significativamente maggiore nel Gruppo A, almeno per quanto riguarda la prima e la seconda misurazione ($P < 0,05$).

Conclusioni. Sebbene il numero di pazienti studiato sia limitato, la FREMS ha evidenziato una certa efficacia nel trattamento del piede diabetico. Questa terapia accelera la guarigione della ferita e riduce il dolore associato sia all'ulcera che alla neuropatia diabetica. Se i dati clinici riferiti dagli Autori saranno confermati da studi eseguiti su casistiche più ampie di pazienti, la FREMS potrà essere proposta come uno strumento utile da combinare con il trattamento classico del piede diabetico.

PAROLE CHIAVE: Ulcera cutanea - Piede diabetico - Stimolazione elettrica - Diabete.

References

1. Wraight PR, Lawrens SM, Campbell DA, Colman PG. Creation of a multidisciplinary, evidence based, clinical guideline for the assessment, investigation and management of acute diabetes related foot complications. *Diabetic Med* 2004;22:127-36.
2. Wolcott LE, Wheeler PC, Hardwicke HM, Rowley BA. Accelerated healing of skin ulcers by electrotherapy. *South Med J* 1969;62:795-801.
3. Gault WR, Gatens PF. Use of low intensity direct current in management of ischemic skin ulcers. *Phys Ther* 1976;56:265-9.
4. Gardner SE, Frantz RA, Schmidt FL. Effect of electrical stimulation on chronic wound healing: a meta-analysis. *Wound Repair Regen* 1999;7:495-503.
5. Carey LC, Lepley D. Effect of continuous direct electric current on healing wounds. *Surg Forum* 1962;13:33-5.
6. Page CF, Gault WR. Managing ischemic skin ulcers. *Am Fam Physician* 1975;11:108-14.
7. Carley PJ, Wainapel SF. Electrotherapy for acceleration of wound healing: low intensity direct current. *Arch Phys Med Rehabil* 1985;66:443-6.
8. Wood JM, Evans PE 3rd, Schallreuter KU, Jacobson WE, Sufit R, Newman J *et al.* A multicenter study on the use of pulse low intensity direct current for healing chronic stage II and stage III decubitus ulcers. *Arch Dermatol* 1993;129:999-1009.
9. Baker LL, Chambers R, DeMuth SK, Villar F. Effects of electrical stimulation on wound healing in patients with diabetic ulcers. *Diabetes Care* 1997;20:405-12.
10. Lundeberg TC, Eriksson SV, Malm M. Electrical nerve stimulation improves healing of diabetic ulcers. *Ann Plast Surg* 1992;29:328-31.
11. Bosi E, Conti M, Vermigli C, Cazzetta G, Peretti E, Cordoni MC *et al.* Effectiveness of frequency modulated electromagnetic neural stimulation in the treatment of painful diabetic neuropathy. *Diabetologia* 2005;48:817-23.
12. Margara A, Merlino G, Borsetti M, Bergamin F, Borsetti G. A proposed protocol for the surgical treatment of pressure sores based on a study of 337 cases. *Eur J Plast Surg* 2003;26:57-61.
13. Ozkan O, Coskunfirat OK, Ozgentas HE. Reliability of free-flap coverage in diabetic foot ulcers. *Microsurgery* 2005;25:107-12.
14. Chen SL, Chen TM, Chou TD, Chang SC, Wang HJ. Distally based sural fasciomusculocutaneous flap for chronic calcaneal osteomyelitis in diabetic patients. *Ann Plast Surg* 2005;54:44-8.
15. Vranckx JJ, Slama J, Preuss S, Perez N, Svensjo T, Visovatti S *et al.* Wet wound healing. *Plast Reconstr Surg* 2002;110:1680-7.
16. Blume PA, Paragas LK, Sumpio BE, Attinger CE. Single-stage surgical treatment of noninfected diabetic foot ulcers. *Plast Reconstr Surg* 2002;109:601-9.
17. Lepantalo M, Biancari F, Tukiainen E. Never amputate without consultation of a vascular surgeon. *Diabetes Metab Res Rev* 2000;16(Suppl 1):S27-32.
18. [No authors listed]. Management of tissue load: An excerpt from the third NPUAP Slide Set. National Pressure Ulcer Advisory Panel. *Adv Wound Care* 1997;10:35-8.
19. Suntken G, Starr B, Ermer-Seltun J, Hopkins L, Preftakes D. Implementation of a comprehensive skin care program across care settings using the AHCPR pressure ulcer prevention and treatment guidelines. *Ostomy Wound Manage* 1996;42:20-2.
20. Abruzzese R. NPUAP and AHCPR. *Decubitus* 1993;6:4.
21. Robinson KR. The responses of cells to electrical fields: a review. *J Cell Biol* 1985;101:2023-7.
22. Demir H, Balay H, Kirnap M. A comparative study of the effects of electrical stimulation and laser treatment on experimental wound healing in rats. *J Rehabil Res Dev* 2004;4:147-54.
23. Tafkan , Ozyazgan I, Tercan M, Kardaf H, Balkanlı S, Saraymen R *et al.* A comparative study of the effect of ultrasound and electrostimulation on wound healing in rats. *Plast Reconstr Surg* 1997;100:966-72.
24. Ericson CA, Nucitelli R. Embryonic fibroblast motility and orientation can be influenced by physiological electric fields. *J Cell Biol* 1984;98:296-307.
25. Bourguignon GJ, Bourguignon LY. Electrical stimulation of protein and DNA synthesis in human fibroblast. *J Fed Am Soc Exp Biol* 1987;1:398-402.
26. Clover AJ, McCarthy MJ, Hodgkinson K, Bell PR, Brindle NP. Noninvasive augmentation of microvessel number in patients with peripheral vascular disease. *Vasc Surg* 2003;38:1309-12.
27. Chekanov V, Rayel R, Krum D, Alwan I, Hare J, Bajwa T *et al.* Electrical stimulation promotes angiogenesis in a rabbit hind-limb ischemia model. *Vasc Endovascular Surg* 2002;36:357-66.
28. Zhao M, Bai H, Wang E, Forrester JV, McCaig CD. Electrical stimulation directly induces pre-angiogenic responses in vascular endothelial cells by signaling through VEGF receptors. *J Cell Sci* 2003;117:397-405.
29. Kanno S, Oda N, Abe M, Saito S, Hori K, Handa Y *et al.* Establishment of a simple and practical procedure applicable to therapeutic angiogenesis. *Circulation* 1999;99:2682-7.
30. Yang HT, Yan Z, Abraham JA, Terjung RL. VEGF 121 and bFGF induced increase in collateral blood flow requires normal nitric oxide production. *Am J Physiol Heart Circ Physiol* 2001;280:H1097-H1104.
31. Dulak J, Jozkowicz A, Dembinska-Kiec A, Guevara I, Zdzienicka A, Zmudzinska-Grochot D *et al.* Nitric oxide induces the synthesis of vascular endothelial growth factor by rat vascular smooth muscle cells. *Arterioscler Thromb Vasc Biol* 2000;20:659-66.
32. Alvarez OM, Mertz PM, Smerbeck RV, Eaglstein WH. The healing of superficial skin wounds is stimulated by external electrical current. *J Invest Dermatol* 1983;81:144-8.
33. Bevilacqua M *et al.* Increase of vascular endothelial growth factor (VEGF) by FREMS. A clinical study in non-insulin dependent diabetics with limb ischemia. Presented at ENDO 2003 - Endocrine Society's 85th Annual Meeting, 2003.
34. Provenzano V, Fleres M, Ajello V *et al.* Impiego dell'elettroterapia LORENZ nel piede diabetico: nostra esperienza. *Diabete* 2004;16(Suppl 1):93.
35. Turrisi E, Sciaraffia M, Barione A *et al.* Elettroterapia Lorenz nei pazienti affetti da diabete tipo 1 e 2 complicato da neuropatia sensitiva e/o AOCIP sintomatiche. Atti del XIV congresso nazionale dell'Associazione dei Medici Diabetologi; Catania 21-23 maggio 2003. p. 427-8.
36. Ciancia D, De Benedictis D, Nicoletti E. Ulcera plantare diabetica trattata con un'innovativa terapia FREMS (Frequency modulated electro-magnetic neural stimulation). Atti del VI convegno "Il piede diabetico, aspetti sistemici e comorbilità". Torino, 2005.
37. Kloth LC. Electrical stimulation for wound healing: a review of evidence from in vitro studies, animal experiments, and clinical trials. *Int J Low Extrem Wounds* 2005;4:23-44.
38. Kloth LC. How to use electrical stimulation for wound healing. *Nursing* 2002;32:17.
39. Kloth LC, McCulloch JM. Promotion of wound healing with electrical stimulation. *Adv Wound Care* 1996;9:42-5.